

## Effect of Fenbendazole Treatment Against *Oxyuris* spp. on Green Iguana (*Iguana iguana*)

Shelly Kusumarini R<sup>1\*</sup>, Garvasilus Privantio Tegar Virgiawan Huler<sup>2</sup>, Rafi Dzakhir Ghalib<sup>2</sup>, Shafa Luvena Pradhantya<sup>3</sup>, Devita Marsya Herina Hapsari<sup>2</sup>, Nofan Rickyawan<sup>3</sup>, Reza Yesica<sup>1</sup>, Nanis Nurhidayah<sup>4</sup>

<sup>1</sup>Department of Parasitology, Faculty of Veterinary Medicine, Universitas Brawijaya

<sup>2</sup>Bachelor Student on Faculty of Veterinary Medicine, Universitas Brawijaya

<sup>3</sup>Department of Surgery and Radiology, Faculty of Veterinary Medicine, Universitas Brawijaya

<sup>4</sup>Research Center for Veterinary Science, National Research and Innovation Agency

\*Corresponding author: shellykusuma224@ub.ac.id

Submitted 3 June 2023, Accepted 24 December 2023

### ABSTRACT

Infection of *Oxyuris* spp., a gastrointestinal nematode, has been reported in reptiles around the world, including in the green iguana (*Iguana iguana*). In most cases, parasite control in reptiles relies on anthelmintics administration. Fenbendazole has been used as the drug of choice for parasite control in reptiles. However, the data of fenbendazole administration for *Oxyuris* spp. infection on green iguana (*Iguana iguana*) in Indonesia was absent. We evaluated the effect of fenbendazole administration (dose: 25 mg/kg body weight [BW] for five consecutive days per oral) for natural infection of *Oxyuris* spp. among thirty-three green iguanas in Malang Raya (Malang District, Malang City, and Batu City). The fecal examination was made through a modified Mc Master technique on the day-0, 7, 14, 21, and 31 post-treatment. The data on management (such as caging, feeding, and health program) conducted by the owners were recorded as well. The result showed that reduction of a hundred percent (100%) of egg per gram (epg) on day-31 post-treatment in all sampled animals. Iguanas were placed in individual and communal cages with daily cleaning and feeding. However, none of the owners arranged health programs such as anthelmintic treatment for their companion reptiles. This study can be used as a recommendation for future control of *Oxyuris* spp. in green iguanas in Indonesia.

**Keywords:** anthelmintic, fenbendazole, *iguana iguana*, Indonesia, *oxyuris* spp.

## INTRODUCTION

Indonesia is home to thousands of faunas, including 753 species of reptiles (Munir *et al.*, 2019). In the modern era, groups of reptiles have been captivated and play a new role as companion animals in the household. One of the most popular companion reptiles in Indonesia is the green iguana (*Iguana iguana*), an herbivore lizard with easy care, unique color, and shapes (Putranto *et al.*, 2017).

Little is known about the diseases in green iguanas in Indonesia, but previous studies reported the infection of the gastrointestinal nematode, namely *Oxyuris* spp. (Oktaviana *et al.*, 2019). The parasite caused mild to moderate effects on the host, including diarrhea, weakness, anorexia, and weight loss (Bolette *et al.*, 2016; Oktaviana *et al.*, 2019). However, fatal cases of green iguana occurred in heavily infected animals and co-infection with other gastrointestinal parasites and bacteria. This induced severe intestinal lesions which may develop into sepsis (Raś-Noryńska and Sokol (2015); Arabkhazaeli *et al.*, (2018).

Control of *Oxyuris* spp. in reptiles become challenging since it was infecting a wide range of other companion reptiles, including; bearded dragon (*Pegona viticeps*), Chinese water dragon (*Physignathus concinus*), veiled chameleon (*Chamaeleo calyptrotus*), and gecko (*Eublepharis macularius*) (Raś-Noryńska and Sokol 2015). This condition is aggravated by a poor management system so high potency of cross-infection among companion reptiles may be present (Oktaviana *et al.*, 2019).

Chemical anthelmintic has been used for major helminth control at least for the last two decades. Fenbendazole, levamisole, piperazine, ivermectin, and praziquantel are the drugs of choice for nematode infection in reptiles (Brames, 2008). According to Giannetto *et al.*, (2007), fenbendazole was 100% effective against oxyurid nematodes which infect reptiles, Herman's tortoises (*Testudo hermanni*) on day-31 post-treatment. Unfortunately, an investigation of its effect on *Oxyuris* spp. infection in Indonesia is

absent. Here, we conducted a study to determine the effect of Fenbendazole treatments in the green iguana infected with *Oxyuris* spp. This study can be used as a recommendation for future control of *Oxyuris* spp. in green iguanas in Indonesia.

## MATERIALS AND METHODS

### Ethical Approval

All procedures of this study have been reviewed and approved by the Institutional Animal Care and Use Committee of Brawijaya University, Malang (Number: 090-KEP-UB-2021).

### Research Design

This study was conducted from August to October 2022 in the Sub-districts of Sukun, Lowokwaru, Dau, Bumiaji, and Junrejo. All those sub-districts were located on Malang Raya (including Malang City, Malang District, and Batu City), East Java, Indonesia. A total of thirty-three captive green iguanas from five different owners were used as the sampled animals (Table 1). The initial sampling was conducted by collecting fecal samples for confirmation of *Oxyuris* spp. infection. One group of nematodes in the Oxyuridae family is called *Oxyuris* spp. The egg's typical shape is an oval (asymmetrical oval) that is flat and blunt, with an operculum on one side. Its length varies between 50 and 60  $\mu\text{m}$  and its width between 20 and 32  $\mu\text{m}$ . The thin, transparent egg wall contains the larva or embryo (Oktaviana *et al.*, 2019). On the other hand, the clinical signs of diseases and the management systems such as caging, feeding systems, cleaning as well as the health program were recorded. Two days after the initial sampling, we administered Fenbendazole at the dose of 25 mg/kg of body weight (BW) for five consecutive days per oral (Hedley, 2020). *Oxyuris*'s egg was counted on day 0 (pre-treatment), day 7, day 14, day 21, and day 31 (post-treatment) to evaluate the egg-positive following drug efficacy outcomes (Aypak *et al.*, 2021).

Table 1. Location and distribution of sampled animals

Owners	Region / Sub-districts	Number of samples (n)	Temperature	Humidity
A	Sukun, Malang City	20	23–32 °C	40–50 %
B	Dau, Malang District	4	23–32 °C	40–50 %
C	Lowokwaru, Malang City	4	22–32 °C	40–50 %
D	Bumiaji, Batu City	2	22–32 °C	50–70 %
E	Junrejo, Batu City	3	22–32 °C	50–70 %

### Fecal Collection and Examination

Fecal sample collection was done from fresh fecal material just after fecal excreted by the sampled animals. Approximately two grams of fecal samples were collected in a plastic bag, labeled and transferred to the Laboratory of Veterinary Parasitology, Faculty of Veterinary Medicine, Brawijaya University, Malang. Fecal sample examination was carried out through McMaster methods (Taylor et al., 2016). Two grams of fecal materials were added with tap water in a plastic glass and homogenized. The mixture then sieved 2 – 3 times into new empty plastic glass. We added 30 ml of sugar floatation solution and pipetted one milliliter to McMaster chamber. Observation and calculation of egg number could be made after several minutes under a microscope with 100 × magnification. The eggs morphometric evaluation using microscope Olympus CX-21 (Olympus Corp., Tokyo, Japan). After identifying *Oxyuris*'s egg, the positive sample was measured by ImageJ software to know the average length of eggs (Taylor et al., 2007; Kusumarini et al., 2021).

The technique for determining how well anthelmintics work against gastrointestinal nematodes is the faecal egg count reduction (FECR). FECRT measures the percentage decrease in worm eggs following anthelmintic treatment (Al-Aliyya et al., 2022).  $FECRT\% = (T_1 - T_2) / T_1 \times 100$ , where  $T_1$  is the pre-treatment egg count and  $T_2$  is the post-treatment egg count. According to Silva et al. (2018), the efficacy of fenbendazole is determined using four

criteria: (1) extremely effective, when the parasite burden is reduced by more than 98%; (2) effective, with a reduction of 90-98%; (3) fairly effective, with a reduction of 80-89%; and (4) less active, with a reduction of <80%.

### Data Analysis

Number of eggs per gram (EPG) of each individual sampled animal was tabulated in Microsoft Excel. Prevalence of infection stated as percent with 95 % confidence interval (CI 95 %).

## RESULT

The initial sampling on 33 iguanas confirmed the presence of *Oxyuris* infection with a hundred percent prevalence. The egg was characterized as follows; transparent, oval, blunt on one side, has an operculum on one side, a thin wall, and contains the worm embryos. The average egg size was 55.80 µm in length and 26.75 µm in width, respectively (Figure 1).

The result of the microscopic examination of the epg numbers is shown in Figure 1. By this study, Fenbendazole treatment at the dose of 25 mg/kg of body weight, per oral, for five consecutive days successfully reduced the epg number of *Oxyuris* spp. on day 31 after-treatment, a hundred percent reduction was observed in all groups (Werther et al., 2000). Moreover, a regaining of appetite can be

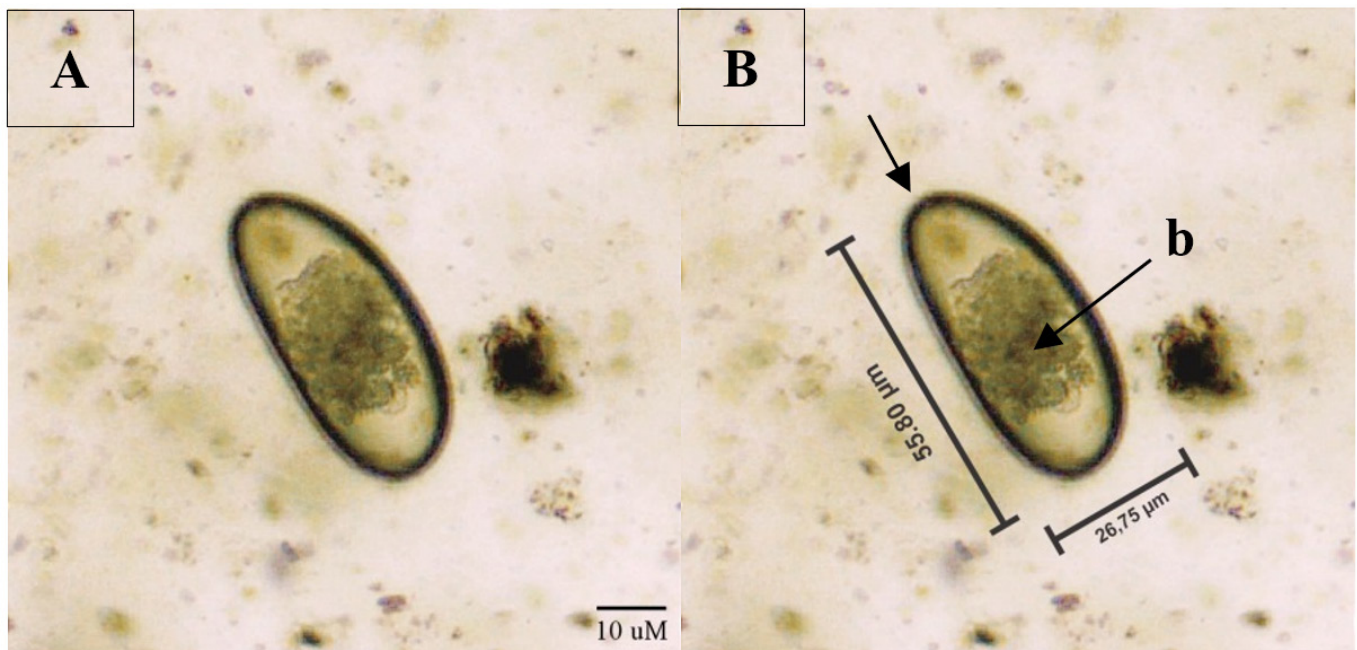


Figure 1. Eggs of *Oxyuris* spp. found in flotation techniques of *Iguana iguana* from Malang Raya showing oval and operculum (a) with embryonated eggs (b). The length of the egg is 26,75 µm, while its width is 55,80 µm. Scale bar 10 µM. (100 x magnifications).



used to assess the effectiveness of oral fenbendazole treatment for helminth infections (Hedley, 2020).

According to the result of the recording on the management, the green iguanas was kept in communal and individual cages with regular daily feeding and cleaning program. They consumed various fruit and vegetables, such as water spinach, lettuce, papaya, and bean sprout (Table 2). However, none of the iguana's owners arranged any deworming program whereas other reptiles were present in the same breeding house (Table 3).

Fenbendazole was administered as an anthelmintic. The average FECRT result was 10.50% on day seven, 90.92% on day fourteen, 97.20% on day twenty-one, and 100% on day thirty-one, when the results reached their peak and no *Oxyuris* spp. eggs were found (Table 4).

## DISCUSSION

This is the first parasitological study to determine the effect of fenbendazole therapy for *Oxyuris* spp. infection of green iguana in Malang Raya, East Java, Indonesia. Microscopic examination of fecal samples confirmed the infection on the green iguana due to the finding of eggs that are typical to *Oxyuris*' egg morphology. According to Oktaviana *et al.* (2019), *Oxyuris*' egg has an oval or asymmetrical oval, blunt and flat at one side, and has an operculum (Figure 1). The egg was containing larvae or embryos with thick

and colorless egg walls. Tiuria *et al.*, (2017) mentioned that the egg size ranged from 43.7 – 68.4 µm in length, and 25.2 – 38.6 µm in width. The anthelmintic drug fenbendazole has shown to be highly successful in destroying adult worms and *Oxyuris* spp. worm eggs, as evidenced by the FECRT findings of 100% on day 31. The anthelmintic fenbendazole was administered to the iguana under observation, and no negative effects or injuries were observed during the entire operation (Werther *et al.*, 2000).

The high prevalence of *Oxyuris* infection in sampled animals found in this study might be related to poor management systems, including; cage hygiene, feed cleanness, population density, type of maintenance cage, and humidity. Some of the green iguanas' owners kept them in a high-density communal cage, so the cleanness of the cage was critical for the iguana's health (Dowling, 2008). According to Hedley *et al.*, (2013), high-density caging is in line with the high contamination of feces in communal cages. The presence of fecal materials is a potential source of helminth infection due to the ingestion of contaminated feed in the cage. Daily cleanness programs should be done by removing the bedding and washing the cage with soap or disinfectant to avoid feed contamination which causes helminth infection (Barten 2003).

Another critical aspect related to the green iguana's health was the temperature and humidity. The average temperature ranges from 22 – 23 °C, while

Table 2. Caging or Housing and Feeding Management for Green Iguana (*Iguana iguana*)

Owners	Cage			Feeding		
	Type	Material	Number per cage	Bedding	Period	Types
A	Communal	Wire	5	Soil	Once a day in the morning	Water spinach, papaya, bean sprout
	Terrarium, Communal	Wire and glass	13	Cement	Once a day in the morning	Water spinach, papaya, bean sprout
	Individual	Iron	1	Iron	Once a day in the morning	Water spinach, papaya, bean sprout
B	Individual	Iron	1	Iron	Once a day	Water spinach, lettuce, papaya, bean sprout
C	individual	Terrarium, glass	1	Paper	Once a day	Papaya, bean sprout, lettuce
	Individual	Iron	1	Iron	Once a day	Papaya, bean sprout, lettuce
D	Communal	Iron	2	Iron	Once a day	Water spinach, lettuce, banana, bean sprout
E	Individual	Iron	1	Iron	Once a day	Lettuce, papaya, bean sprout,

average humidity was 70 % in study sites. The reptiles, including iguanas, need the ideal temperature and humidity to maintain their health as well as optimize the digestive metabolic process since they are poikilothermic animals. The ideal temperature for most reptiles ranges from 26 – 32 °C and 65 – 75 % of humidity (Barten, 2003; Giannetto *et al.*, 2007; Serra-Campos *et al.*, 2022). The higher or lower required temperature and humidity enabled to induce of immunosuppression so the animals became more susceptible to diseases.

Since the data on daily egg output of *Oxyuris* spp. on the green iguana is absent, we unable to classify the infection intensity. However, the number of egg expelled in the host feces was determined by the parasite's species, number of adult stages in the intestine, fecal consistency, as well as host immunity (Hansen and Perry 1994). The determination for the actual parasite number in each iguana could not be conducted due to the worm count technique was not feasible in the alive green iguana and other exotic animals. Further investigation is needed to measure the daily egg output for determination of infection intensity.

Although all of sampled animals did not show any clinical symptoms, but mild to severe, even death related to *Oxyuris* infection has been reported in the past. Some of clinical symptoms such as large intestinal obstruction, cloacal prolapse, anorexia might be present in severely infected individual. The mechanism of fatal case was explained by Raś-Noryńska and Sokol (2015) and Arabkhazaeli *et al.*, (2018). The presence of parasites in the colon obstructed the blood supply and damaged the colon tissues which indicated perforations to the abdominal cavity. This condition induced peritonitis to sepsis which put iguana at the risk of death.

According to this study, control of *Oxyuris* infection with fenbendazole enabled to reduce the epg in day-31 post treatments. Previously, fenbendazole has been known to be effective for nematode control of iguana in Brazil which indicated by nematode epg reduction and increase appetite of iguana. Fenbendazole was also found to be effective to control nematode infection in others reptile such as turtle (Giannetto *et al.*, 2007).

Fenbendazole is a broad spectrum anthelmintic which effective for immature and adult stage of

Table 3. Cleaning and Health Management for Green Iguana (*Iguana iguana*)

Owners	Cage Type	Cleaning period	Presence of Other Reptiles		Deworming program
			Yes / No	Group	
A	Communal	Once a day in the morning with tap water	Yes	Snake, gecko, Varanus lizard	No
	Terrarium, Communal	Once a day in the morning with tap water	Yes	Snake, gecko, Varanus lizard	No
	Individual	Once a day in the morning with tap water	Yes	Snake, gecko, Varanus lizard	No
B	Individual	Once a day with tap water	Yes	Snake, gecko, bearded dragon	No
C	individual	Once a day with tap water	Yes	Gecko	No
	Individual	Once a day with tap water	Yes	Gecko	No
D	Communal	Once a day with tap water	No	No	No
E	Individual	Once a day with tap water	No	No	No

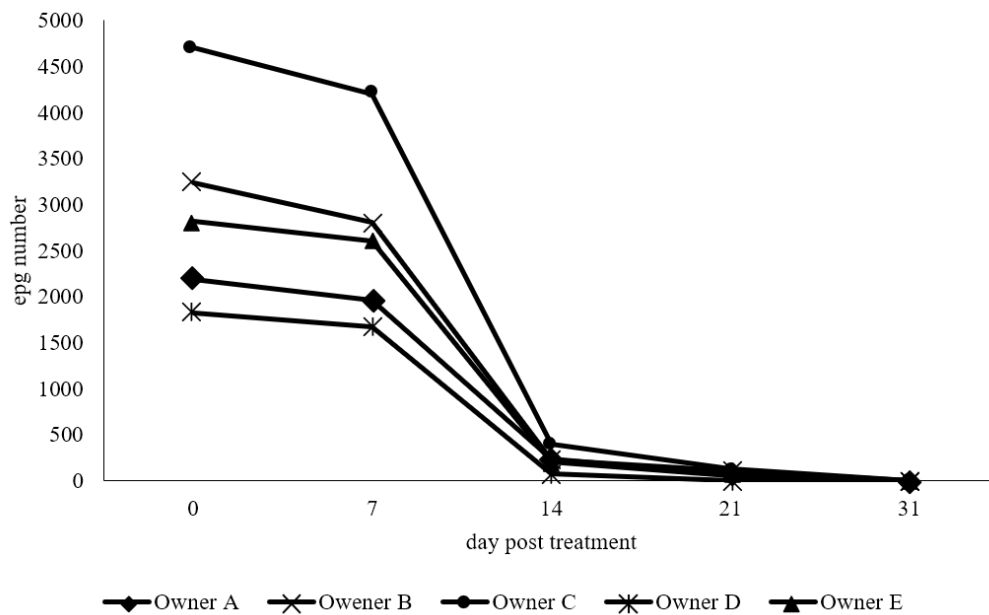
Table 4. Comparison of FECRT among the three groups on days 7, 14, 21, and 31 after fenbendazole treatment in *Iguana iguanas* infected with *Oxyuris* spp.

Day	$\bar{x}$ EPG Before treatment	$\bar{x}$ EPG After treatment	$\bar{x}$ FECRT (%)
0	2654,54	-	-
7	2654,54	2375,75	10,50
14	2654,54	240,90	90,92
21	2654,54	74,24	97,20
31	2654,54	0	100

\*EPG Eggs per gram; FECRT Fecal Egg Count Reduction Test

Table 5. Egg per gram (epg) number of *Oxyuris* spp. in day 0, 7, 14, 21 and 31 days post-treatment in Green Iguana

Owners	EPG day-				
	0	7	14	21	31
Owner A	2188.00	1960.00	235.00	68.00	0.00
Owner B	3238.00	2812.50	225.00	112.5	0.00
Owner C	4700.00	4200.00	400.00	125.00	0.00
Owner D	1825.00	1675.00	75.00	0	0.00
Owner E	2816.67	2600.00	200.00	50	0.00

Figure 2. Egg per gram (epg) number of *Oxyuris* spp. in day 0, 7, 14, 21 and 31 days post-treatment in Green Iguana

helminths. Düwel (1977) mentioned that the efficacy of fenbendazole was related to its mechanism of action. Fenbendazole works by blocking the intracellular microtubular transport system and damage tubulin so that it can prevent tubulin polymerization and inhibit microtubule formation. It also blocked the metabolic pathways of helminths by inhibition of metabolic enzyme such as malate dehydrogenase and fumarate reductase enzymes and followed by the inhibition of glucose absorption and energy formation. Since the process of glucose absorption inhibition occurred slowly, so it will be better to follow the administration of fenbendazole periodically in 3 – 5 days. The helminths die due to energy insufficiency (Heggem, 2008; Plumb, 2011; Zilfa et al., 2022).

Fenbendazole was also known has the ovicidal effect since it enabled to damage the structure of the nematode egg wall by binding to proteins present in the vitelline membrane or the outermost layer of the eggshells. The ovicidal properties of fenbendazole

prevent the formation of spindle fibers needed for cell division and preparation for the larval development (Astuti et al., 2017; Al-Aliyya et al., 2022).

The most challenging points were in terms of drug administration (precise dosage and proper administration) and stress avoidance in targeted animals. Since the coinfection might be present, Ekici et al. (2011) recommended the use of combination of ivermectin (0.2 mg/kg, per oral) and praziquantel (10 mg/kg, subcutaneous injection) as a selective treatment nematode and cestode in green iguana. Albendazole (50 - 70 mg / kg, per oral) and oxfendazole (68 mg / kg, per oral, repeated in two weeks) have also been reported to be effective for helminths infection in iguana reported by Stahl (2003) and Yazar (2010). In conclusion, the dose of fenbendazole (25 mg/kg BW for five consecutive days) was promising for cheaper and simpler future control of nematodes in the green iguana.

## ACKNOWLEDGEMENTS

The authors thank BPPM Faculty of Veterinary Medicine, Universitas Brawijaya, Surabaya, Indonesia, for providing funds with Grant No. 2072/UN10.F13/TU/2022.

“The authors state that they have no known conflicting financial interests or personal ties that may be seen as having influenced the work described in this study.”

## REFERENCE

- Al-Aliyya, R. F. D., Ida A. P. A., & Gusti A. Y. K. 2022. Efektivitas Albendazol terhadap Cacing Nematoda Sapi Bali di Kelompok Tani Suka Dharma, Baturiti, Tabanan. *Buletin Veteriner Udayana*. 14(5): 470-478.
- Arabkhzaeli, F., Rostami, A., Gilvari, A., Nabian, S., and Madani, S. A. 2018. Frequently Observed Parasites in Pet Reptiles' Feces in Tehran. *Iranian Journal of Veterinary Medicine, Online First*, 12 (1): 19-25.
- Astuti, K. R. K., Ida, B. K. A., & Made, S. A. 2017. Efek Ovicidal Albendazole 10% terhadap Telur Cacing *Fasciola gigantica* secara In Vitro. *Indonesia Medicus Veterinus*, 6(5): 363-369.
- Aypak, S., Cavit, K., Metin, P., Adnan, A., Tulin, K. 2021. Evaluation of Orally Administered Anthelmintic Treatment Option for *Dentostomella translucida* in Naturally Infected Mongolian Gerbil (*Meriones unguiculatus*). *Turkiye Parazitoloj Derg*, 45(1); 17-21.
- Barten, S. L. 2003. *Green Iguana Management and Husbandry*. 10(4): 13.
- Bolette D.P., Lijia C., Rogers M. B. 2016. *Enterobius (Enterobius) shriveri* n. sp. (Nematoda: Oxyuridae: Enterobiinae) from *Macaca fascicularis* Raffles, 1821 (Primates: Cercopithecidae: Cercopithecinae) and Three Other Cercopithecoid Primate Species: With Additional Information on *Enterobius (Enterobius) macaci* Yen, 1973. *Comparative Parasitology*, 83(1):54-73.
- Brames, H. 2008. Efficacy and Tolerability of Profender in Reptiles: Spot-on Treatment Against Nematodes. *Exotic DVM*, 10 : 29–34.
- Dowling, A. 2008. *Husbandry Manual for the Green Iguana (Iguana Iguana)*. Western Sydney Institute of TAFE, Richmond.
- Düwel, D. 1977. Fenbendazole. II. Biological properties and activity. *Pesticide Science*, 8(5), 550-555.
- Ekici, O.D, Isik, N, & Guclu, F. 2011. Gastrointestinal Parasites Found in A Green Iguana (*Iguana iguana*). *Eurasian J. Vet. Sci*, 27(2) : 131–134
- Giannetto, S., Brianti, E., Poglayen, G., Sorgi, C., Capelli, G., Pennisi, M. G., & Coci, G. 2007. Efficacy of oxfendazole and fenbendazole against tortoise (*Testudo hermanni*) oxyurids. *Parasitology Research*, 100(5) : 1069–1073.
- Hansen J., Perry B. International Laboratory for Research on Animal Diseases; Nairobi, Kenya: 1994. The Epidemiology, Diagnosis and Control of Helminth Parasites of Ruminants 158–168.
- Hedley, J., Eatwell, K., Shaw, D.J., 2013. Gastrointestinal Parasitic Burdens In UK Tortoises: A Survey Of Tortoise Owners and Potential Risk Factors. *Veterinary Record* 173, 525–525.
- Hedley J. 2020. *BSAVA Small Animal Formulary 10th edition: Part B Exotic Pets*. BSAVA.
- Heggem, B. 2008. Fenbendazole. *Journal of Exotic Pet Medicine*, 17(4) : 307–310.
- Kusuma, S., Yesica, R., Bagus, G. R. W., Hermanto, I., Nurholizah, Y., & Widyaneni, T. M. 2021. Preliminary Study: Detection of Ecto and Endoparasites Among Wild Rats From Urban Area in Blimbing, Malang, East Java. *Acta Veterinaria Indonesiana*, 5, 95-101.
- Munir, M., Hamidy, A., Riyanto, A., Anita, S., Kusriani, M. 2019. Indonesian Herpetofauna: Past and Future Challenge. The 58th Annual Meeting of Herpetological Society of Japan.
- Oktaviana, V., Yudhana, A., & Amanda, N. 2019. Laporan Kasus: Infeksi Cacing Oxyuris spp. pada Iguana iguana (*Iguana iguana*). *Jurnal Medik Veteriner*, 2(2) : 152-157.
- Plumb, D. C. 2011. *Plumb's Veterinary Drug Handbook (7th Edition)*. PharmaVet Inc. Stockholm, Wisconsin.
- Putranto, D. I., Yuda, P., & Zahida, F. 2017. Keanekaragaman Reptil Impor di Yogyakarta. *Biota : Jurnal Ilmiah Ilmu-Ilmu Hayati*, 117–125.
- Raś-Noryńska, M., & Sokół, R. 2015. Internal Parasites of Reptiles. *Annals of Parasitol*, 61(2) : 115-117.
- Serra-Campos, A. O., Abreu-Junior, A. N. G., Nascimento, A. A., Abidu-Figueiredo, M., Lima, M. S. C. S., & Machado-Santos, C. 2022. Gastroesophageal tube of the Iguana iguana (*Iguanidae*): Histological description, histochemical and immunohistochemical analysis of 5-HT and SS cells. *Brazilian Journal of Biology*, 83 : 1519-6984.
- Silva F.F., Bezerra, H.M.F.F., Feitosa, T.F., & Vilela, V.L.R. 2018. Nematode resistance to five anthelmintic classes in naturally infected sheep herds in northeastern Brazil. *Rev. Bras. Parasitol. Vet*, 27(4): 423-429
- Stahl, S. J., 2023. Pet Lizard Conditions and Syndromes. *Semin Avian Exotic Pet Med*, 12(3), 62-182.
- Taylor, M. A., R. L. Coop. and R. L. Wall. 2007. *Veterinary Parasitology 3rd Ed*. Blackwell Publishing Ltd. Oxford.
- Taylor, M.A, R.L. Coop, & R.L. Wall. 2016. *Veterinary Parasitology 4th edition*. Hoboken: Blackwell Publishing.

- Tiuria, R., Pratiwi, U., Tumbelaka, L., 2017. Parasitic Worm in Tiger (*Panthera tigris*) at Serulingmas Zoological Garden Banjarnegara, Bandung Zoological Garden, and Indonesia Safari Park Bogor, *Jurnal Veteriner* 18(1), 1-10.
- Werther, K., Vicente, J.J., de Petra, C.B., 2000. Description of a gastrointestinal parasite found in an iguana (*Iguana iguana*) in Brazil. Dept of Patholog, College Vet Med, Univ-Georgia.
- Yazar, E. 2010. Surungenler, in: Egzotik Hayvan Hastalikhari ve Beslenmesi, Ed: Madem M, Erman Ofset, Konya.
- Zilfa, S. Yudha F., Arman S., Farid A., Abdullah H. & Wahyu E. S. 2022. Efektivitas Antelmintik Sebelum dan Sesudah Pemberian pada Gajah Sumatra (*Elephas maximus sumatranus*) di Lokasi Conservation Response Unit (CRU) dan Pusat Konservasi Gajah (PKG) Aceh. *Jurnal Ilmiah Mahasiswa Veteriner*, 6(3) : 121-126.