

The Features of Seminiferous Tubule Cells in Rat Testicular Dysfunction Induce by Secretome Based On Cytoskeletal Protein Profile

Surya Agus Prihatno¹, Irma Padeta², Arinda Devi Larasati², Betty Sundari², Annisa Hidayati², Yuda Heru Fibrianto³ and Teguh Budipitojo^{2*}

¹Department of Reproduction and Obstetrics, Faculty of Veterinary Medicine, Universitas Gadjah Mada, Yogyakarta, 55821, Indonesia

²Department of Anatomy, Faculty of Veterinary Medicine, Universitas Gadjah Mada, Yogyakarta, 55821, Indonesia

³Department of Physiology, Faculty of Veterinary Medicine, Universitas Gadjah Mada, Yogyakarta, 55821, Indonesia.

*Corresponding author's email: budipitojo@ugm.ac.id

Keywords: cisplatin, cytokeratin, secretome, testicular dysfunction, vimentin.

INTRODUCTION

Secretome is a factor found in the stem cell culture medium. This factor may repair the tissues of the organs that were damaged by various degenerative disorders¹. A previous study has reported that secretome derived from the fetal human umbilical cord mesenchymal stem cell (HUC-MSC) may be an effective regenerative agent for β -cell pancreatic regeneration in Type 1 diabetes mellitus and for skin regeneration in incisional and burn wound healing.

The administration of cisplatin as a chemotherapeutic agent is limited because it causes side effects, such as reproductive toxicity and progresses to testicular dysfunction². As a degenerative disorder, testicular dysfunction is characterized by failure in the synthesis of reproductive hormones and spermatogenesis. Cisplatin-induced testicular cell damage would promote vimentin and cytokeratin localization in the spermatogenic, Sertoli, and Leydig cells.

Studies on the use of secretome in promoting the recovery of various degenerative disorders and its effects on the spermatogenesis of rats with cisplatin-induced testicular dysfunction have not been conducted. The aim of this study was to investigate the effect of secretome derived from HUC-MSC on cisplatin-induced testicular dysfunction in rats.

MATERIALS AND METHODS

Thirty-six male Wistar rats were adapted for 7 days before the administration of cisplatin, and these rats were fed with basal food and water *ad libitum* and were divided into the control and secretome-treated groups. Testicular dysfunction was induced by cisplatin at the dose 3 mg/kg BW³ intraperitoneally 3 times with 3 days' interval.

The secretome-treated group was further divided into the low- and high-dose secretome-

treated group. Secretomes were injected intraperitoneally once a week for 4 weeks at a dose of 0.2 and 0.5 mL/kg BW in the low- and high-dose secretome-treated groups, respectively. The rats were sacrificed every 1 week after the injection of secretome, and the cauda epididymis of the rat was collected then processed by paraffin method for immunohistochemistry staining by using vimentin and cytokeratin primary antibody. The result were analyzed descriptively.

RESULT AND DISCUSSION

1 week after the first secretome injection, the vimentin immunoreactivity of the low-dose group was weak in the spermatogonia, moderate in the primary spermatocytes and strong in the spermatozoa and Sertoli cells (Figure 1A1). In the high-dose group, vimentin immunoreactivity was weak in the primary spermatocytes and moderate in the spermatid and Sertoli cells (Figure 1A2). Vimentin immunoreactivity was not observed in the Leydig cells of the two groups. 1 week after the second secretome injection in the low-dose group, vimentin immunoreactivity was weak in the spermatogonia, moderate in the primary spermatocytes and strong in the spermatozoa, Sertoli cells, and Leydig cells (Figure 1B1). Meanwhile, in the high-dose group, vimentin immunoreactivity in the spermatogonia and Leydig cells, spermatocytes, and spermatozoa and Sertoli cells was strong, moderate, and extremely strong, respectively (Figure 1B2). 1 week after the third secretome injection in the low-dose group, vimentin immunoreactivity in the primary spermatocytes and Leydig cells and spermatozoa and Sertoli cells were weak and moderate, respectively. However, vimentin immunoreactivity was not observed in the spermatogonia (Figure 1C1). In the high-dose group, vimentin immunoreactivity was weak in the spermatogonia

and primary spermatocytes. It was moderate in the Leydig cells and strong in the spermatozoa and Sertoli cells (Figure 1C2). After the last secretome injection, vimentin immunoreactivity in the primary spermatocyte and Leydig cells was weak, and that in the spermatozoa and Sertoli cells was moderate. However, it was not observed in the spermatogonia (Figure 1D1).

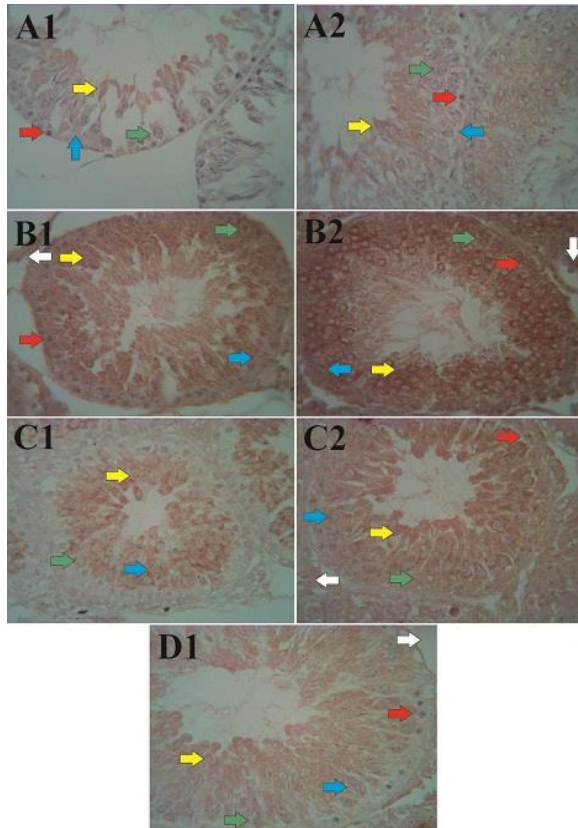


Figure 1. Vimentin immunoreactivity after secretome injection (immunohistochemistry; 500× magnification). In the low-dose group (A1), 1 week after the first secretome injection, a strong vimentin immunoreactivity was observed in the spermatozoa (yellow arrow) and Sertoli cells (blue arrow), whereas in the high-dose (A2) group, the immunoreactivity was moderate. In the low-dose group (B1), 1 week after the second secretome injection, a strong vimentin immunoreactivity was still observed in the spermatozoa and Sertoli cells. Meanwhile, in the high-dose group (B2), the immunoreactivity was very strong in the same cell. In the low-dose group (C1), 1 week after the third secretome injection, moderate vimentin immunoreactivity was observed in the spermatozoa and Sertoli cells, whereas in the high-dose group (C2), the immunoreactivity was strong in the same cells. Then, 1 week after the last injection in the high-dose group (D1), the vimentin immunoreactivity was moderate in the spermatozoa and Sertoli cells. Spermatogonia (red arrow), primary spermatocytes (green arrow), and Leydig cells (white arrow).

1 week after the first secretome injection in the low-dose group, cytokeratin immunoreactivity was weak in the spermatozoa and Sertoli cells. (Figure 2A1). Meanwhile, in the high-dose group, cytokeratin immunoreactivity was weak in the spermatozoa, Sertoli cells, and Leydig cells (Figure 2A2). 1 week after the second secretome injection in the low-dose group, cytokeratin immunoreactivity was moderate in the spermatogonia, primary spermatocytes, spermatozoa, and Sertoli cells, and it was strong in the Leydig cells (Figure 2B1). In the high-dose group, cytokeratin immunoreactivity was weak in the spermatogonia and primary spermatocytes. Meanwhile, cytokeratin immunoreactivity was moderate in the spermatozoa and Sertoli cells and very strong in the Leydig cells (Figure 2B2). 1 week after the third secretome injection in the low-dose group, cytokeratin immunoreactivity was weak in the spermatogonia, primary spermatocytes, spermatozoa, and Leydig cells. However, it was moderate in the Sertoli cells (Figure 2C1). In the high-dose group, cytokeratin immunoreactivity was moderate in the spermatogonia and spermatozoa and strong in the Sertoli and Leydig cells (Figure 2C2). 1 week after the last secretome injection in the high-dose group, cytokeratin immunoreactivity was weak in the primary spermatocytes, moderate in the spermatogonia and strong in the spermatozoa, Sertoli cells, and Leydig cells (Figure 2D1).

Testicular toxicity is one of the serious side effects of cisplatin, which is used in chemotherapy, which causes loss of spermatogonia⁴, abnormalities in the Leydig cells, and suppression of testosterone production^{2,4}. Cisplatin-induced testicular cell damage is caused by oxidative stress, which induces cellular damage by the generation of reactive oxygen species². In the present study, the regenerative effect of secretome is characterized by the presence of spermatogenesis.

Vimentin and cytokeratin, which are intermediate filaments, were observed in this present study. Vimentin distribution depends on the spermatogenesis cycle, and they would be distributed along with the head of the spermatozoa. Vimentin would maintain the integrity of the spermatogenic cells and their connection. Another study has reported that vimentin was also found in the Leydig cells of mature or immature testes. Vimentin was observed in the spermatogenic, Sertoli, and Leydig cells because vimentin supported and controlled the cell structure and function of fetuses or adults⁵. Very strong vimentin immunoreactivity indicated a regenerative process.

Cytokeratin was found in the Sertoli cells during the development stage only. Secretome that contains growth factors and cytokines, which are

regenerative agents, might play a role in the formation of cytokeratin in adult rats with cisplatin-induced testicular dysfunction. The dynamic increase and decrease in the immunoreactivity of vimentin and cytokeratin might be caused by high inflammation reaction by endogenous cytokines. The use of secretome in diabetic rat could repair β -cells of the treatment which is provided earlier. However, it could not maintain the β -cells if the treatment is provided later. It was suggested that exogenous tumor necrosis factor- α and interleukin (IL) in secretome would stimulate severe inflammation reaction⁶.

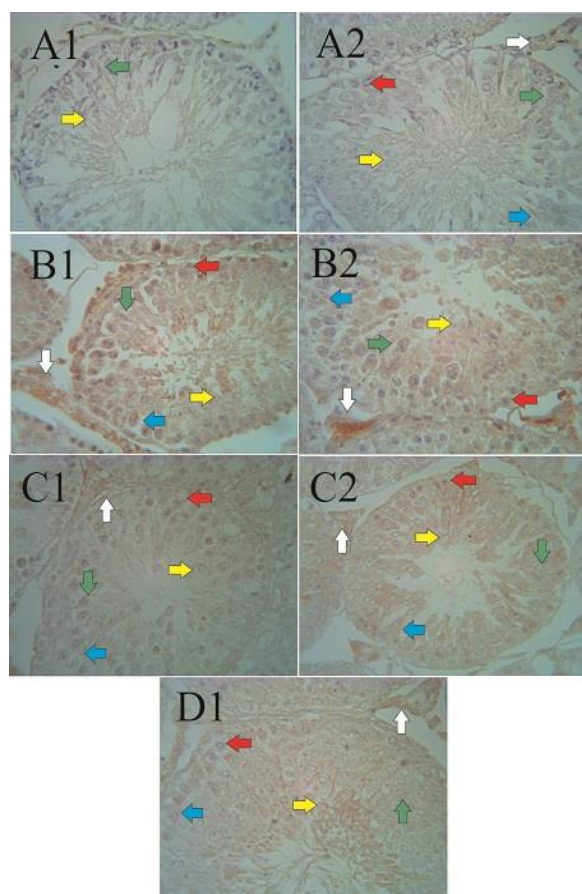


Figure 2. Cytokeratin immunoreactivity after secretome injection (immunohistochemistry; 500 \times magnification). In the low-dose group (A1), 1 week after the first secretome injection, a weak cytokeratin immunoreactivity was observed in the spermatozoa (yellow arrow), whereas in the high-dose group (A2), the immunoreactivity was weak in all spermatogenic cells, Sertoli cells (blue arrow), and Leydig cells (white arrow). In the low-dose group (B1), 1 week after the second secretome injection, a strong cytokeratin immunoreactivity was observed in the Leydig cells, whereas in the high-dose group (B2), very strong immunoreactivity was noted in the Leydig cells. In the low-dose group (C1), 1 week after the third secretome injection, moderate cytokeratin immunoreactivity was observed in the spermatozoa and Sertoli cells, whereas in the high-

dose group (C2), a strong immunoreactivity was found in the Sertoli and Leydig cells. Then, 1 week after the last injection, the high-dose group (D1) showed a strong cytokeratin immunoreactivity in the spermatozoa and Sertoli and Leydig cells.

Severe inflammation might inhibit vimentin and cytokeratin formation. In normal conditions, Leydig cells might secrete cytokines, such as IL-1 and IL-6. Macrophages were present in the testicular interstitium, and they may stimulate Leydig cells to produce cytokines. An *in vitro* study has reported that IL-1 and IL-6 also influenced the Sertoli cells⁷. However, the structures of the seminiferous tubules and cell morphology were normal.

CONCLUSION

Secretome injections were effective 1 week after the second secretome injection that was administered at the high dose. That is, the immunoreactivity of vimentin and cytokeratin was very strong. However, secretome could promote the regeneration of seminiferous tubules based on cytoskeletal protein profile in both the groups.

ACKNOWLEDGMENTS

Authors would like to thank the Directorate General of Higher Education, Ministry of Research, Technology and Higher Education for fully funding this study (Grant number: 160/UN1/DITLIT/ DIT-LIT/LT/2017).

REFERENCES

- [1] Pawitan, J.A. 2014. Prospect of stem cell conditioned medium in regenerative medicine. *Biomed. Res. Int.*, 2014: 1-14.
- [2] Ahmed, E.A., Omar, H.M., Ragb, S.M. and Nasser, A.Y. 2011. The antioxidant activity of vitamin C, DPPD and L-cysteine against cisplatin-induced testicular oxidative damage in rats. *Food Chem. Toxicol.*, 49: 1115-1121.
- [3] Reddy, Y.V.K., Reddy, P.S. and Shivalingam, M.R. 2010. Cisplatin or carboplatin caused suppression in antioxidant enzyme defense system in liver, kidney and testis of male albino rats. *J. Biomed. Sci. Res.*, 2(1): 23-28.
- [4] Reddy, K.P., Madhu, P. and Reddy, P.S. 2016. Protective effects of resveratrol against cisplatin-induced testicular and epididymal toxicity in rats. *Food Chem. Toxicol.*, 91: 65-72.
- [5] Sasaki, M., Yamamoto, M., Arishima, K. and Eguchi, Y. 1998. Effects of follicle-stimulating hormone on intermediate filaments and cell division of Sertoli cells of fetal rat testis in culture. *J. Vet. Med. Sci.*, 60: 35-39.
- [6] Budipitojo, T., Padeta, I., Nugroho, W.S. and Fitriana, I. 2018. Temporal recovery of pancreatic β -cells in Type 2 diabetes mellitus

- induced by mesenchymal stem cell-conditioned medium. *Adv. Life Sci. Tech.*, 62: 14-19.
- [7] Cudicini, C., Lejeune, H., Gomez, E., Bosmans, E., Ballet, F., Saez, J. and Jegou, B. 1997. Human Leydig cells and Sertoli cells are producers interleukins-1 and-6. *J. Clin. Endocrinol. Metabol.*, 82(5): 1426-1433.