

## Fracture Fixation between Os Lumbalis II and III on a Three Month Old Kitten Using Parallel Technique

Siti Zaenab<sup>1\*</sup>, Ivan Satriawan<sup>2</sup>, Osye S. Alamsari<sup>1</sup>, Eva Zulfiati<sup>1</sup>, Benda Alifianti<sup>1</sup>, Hidayati<sup>1</sup>, Deni Noviana<sup>3</sup>

<sup>1</sup>My Vets Animal Clinic Kemang Jakarta, <sup>2</sup>Gloriavet Bandung,

<sup>3</sup>Division of Surgery and Radiology Faculty of Veterinary Medicine, Bogor Agricultural University

\*corresponding author

Corresponding email: myvets001@gmail.com

**Keywords:** fixation, fracture, os lumbalis, parallel technique.

### INTRODUCTION

Spinal fractures, luxations, and fracture-luxations in dogs and cats are common and are often the result of vehicular injury. Other frequent causes of injury include animal attacks or falling from a height. Reports that describe the distribution of spinal column injuries indicate that they affect the lumbar vertebrae most frequently, followed by sacrococcygeal, thoracic, and cervical vertebrae<sup>2,3</sup>.

### CASE REPORT

**Signalment, anamneses, and clinical signs.** A three month old kitten was bitten by a dog a week before, both hind legs could not be used properly.

**Physical examination.** Physical examination showed the kitten was still active and had a good appetite. Neurologic examination revealed negative reaction on proprioceptive and patella reflex on both hind legs.

**Differential diagnose.** Differential diagnoses include paresis, paralysis, hemivertebrae.

**Diagnose.** Radiographically showed fracture between os lumbalis II and III.

**Prognosis.** Prognosis of the surgery is fausta but neurologic damage on both extremitas pelvina might be permanent.

**Treatment.** Pre surgery was done by giving intravenosa fluid by vena cephalica, ceftriaxone intravenosa injection (30 mg/kg BW) and pethidine sub cutaneous injection (2 mg/kg BW). Surgical correction was attempted under general anaesthetics using combination of medetomidine (0,02 mg/kg BW) as sedation and ketamine (10 mg/kg BW) and diazepam (0,5 mg/kg BW) as preanaesthesia and isoflurane as inhalation anaesthetics.

Position the cat in a sternal recumbency and performed dorsal approach skin incission with bilateral exposure of the dorsal lumbar spinous processus and laminae. At least two or three lumbar segments cranial and caudal region of fractured lumbar must be exposed.

Incised through subcutaneous fat and fascia to reach the thoracolumbal. Incise fascia to expose an underlying second layer of fat and the thoracolumbal musculature. Clear the musculature of the pedicle until the processes spinous exposed.

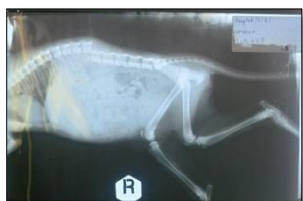

Figure 1. Lateral Recumbency Radiograph

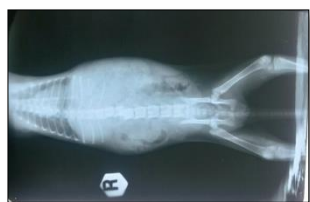

Figure 2. Dorso ventral Recumbency Radiograph

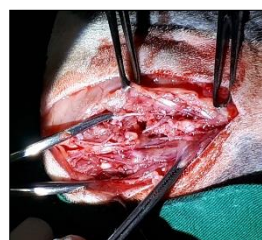

Figure 3. Exposing the processes spinous

Place penetrating bone-holding forceps on the dorsal of spinous processes cranial and caudal to the fracture, and use this gently to reduce the fracture. Visualize the adjacent articular processes articulation to help judge the appropriate level of reduction. Manually drilled holes through the base of the dorsal of spinous processes to be included into the fixation, using 0.045 K-wire. Stay above the dorsal lamina when

drilling the holes.

Pass lengths of the orthopedic wire through the hole and lay them flat. Choose to intramedullary (IM) pins at appropriate thickness for the patient. Using the hand-held or wire twister band the ends of the IM pins so that they can be placed around the cranial and caudal dorsal processes spinous at limit of the fixation. Placed these IM pins on top of the previously place orthopedic wire to lay against the dorsal lamina. Tighten the orthopedic wires around the IM pins using a wire twister.

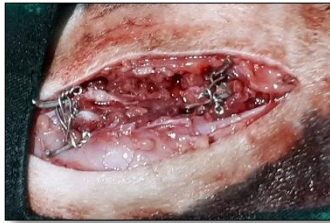

Figure 4. Placed position of pin and wire

Sutured back the musculature, fascia, and subcutaneous tissue on top the fixation area by using simple continuous PGA 3-0.

**Post treatment.** Radiographs examination was done post surgery to confirm the position of os lumbalis. Urination and defecation might be disrupted, acupuncture could help. Physiotherapy and rehabilitation might be needed.

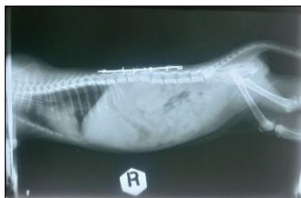


Figure 5. Lateral recumbency radiograph

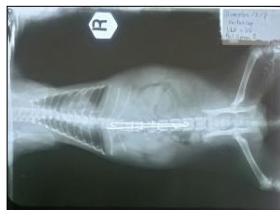

Figure 6. Dorso ventral recumbency radiograph

## DISCUSSION

Complication of surgery for thoracolumbal spinal cord injury include neurologic worsening post-surgery, improper implant placement (eg: iatrogenic damage to the spinal cord, poor bone purchase), implant failure, implant migration, iatrogenic pneumothorax (with cranial and mid thoracic vertebral fixation), post surgery infection, and post surgery seroma<sup>1</sup>.

In this kitten case, surgery may cause complications include poor alignment of the bone

pieces, swelling putting pressure on the spine, infection, and movement of the implant. We should pay attention to the diameter of the pin and also the ability of walk post surgery. We have to repeat neurologic examination regularly.

In the absence of the deep pain perception in this kind of trauma convince of poor prognosis. Estimates for functional recovery in such patient are generally less than 10%<sup>1</sup>.

## CONCLUSION

Stabilization of the fracture could be achieved but the neurologic damage could not be avoided. As long as the urination and defecation is maintained the patient can live almost a normal life.

## REFERENCES

- [1] Fossum, T.W., Dewey, C.W., Horn, C.V., Johnson, A.L., M. Macphail, C., Radlinsky, M.G., Schulz, K.S., dan Willard, M.D. 2013. Small Animal Surgery, Fourth Edition. Mosby Inc., USA.
- [2] Matthiesen DT. Thoracolumbar spinal fractures/luxations: Surgical management. *Comp Cont Ed Sm Anim Pract* 1983; 5: 867-878.
- [3] McKee WM. Spinal trauma in dogs and cats: Review of 51 cases. *Vet Rec* 1990; 126: 285-289.